

# Pulmonary Actinomycosis Complicated by Pneumothorax Treatment

LEO V. SCHNEIDER, M.D., F.A.C.P., F.A.C.C.P. and  
DANIEL LEO FINUCANE, M.D., F.A.C.P., F.A.C.C.P.  
*Glenn Dale, Maryland*

## *Introduction*

Pulmonary actinomycosis in human beings is still a comparative rarity in the United States. On the European Continent, and particularly in Germany, Austria, and Russia, lung infection with actinomycosis is seen fairly often.

The old theory that actinomycosis is contracted by chewing straws and grasses is at present held not to be well founded; at least from the clinical standpoint, this hypothesis in cases reported in the literature has not been substantiated. Aspiration as a means of infection was definitely proved in a number of cases by finding aspirated foreign bodies such as pieces of carious teeth surrounded by the organism. The infection apparently takes place by direct aspiration of infective material through the air passages and occasionally by way of metastasis through the blood stream. The cavity of a carious tooth appears to be a frequent seat of actinomycotic infection. It is uncertain whether or not the actinomyces are able to pass through an intact mucous membrane. However, a number of cases are on record in which infection followed wounds or injuries. During the World War, for instance, we saw a number of cases, where soldiers who had sustained abdominal and pelvic injuries were later found to have actinomycosis, probably as a result of having been bedded on grain stalks and straw. The actinomyces, in these cases, undoubtedly entered by the open wounds.

## *Diagnosis*

The clinical diagnosis of pulmonary actinomycosis is not an easy one to make. The symptomatology of the disease does not have any specific characteristics. It may resemble that of pulmonary tuberculosis, or in some cases, the clinical manifestations may suggest malignancy or syphilitic infection of the lungs. The disease apparently begins as a chronic bronchitis or pneumonia with evidence of a spreading, caseating process in

the lungs and later shows a definite tendency to produce large solitary pulmonary abscesses or cavities surrounded by rather dense caseous infiltration and exudation. Not until metastatic sinuses (abscesses) develop in different parts of the body can the true nature of the disease be suspected and recognized. Even then, repeated histologic examinations, cultures, and exploratory excisions are required in order to arrive at a correct diagnosis. Roughly, there apparently are two main clinical stages in the development of pulmonary actinomycosis. The first stage of the disease is characterized by the development of a bronchial catarrh with a moderate amount of expectoration. During the second stage of infection, the process is extended to the lung tissue, productive cough increases in severity and annoyance, sputum becomes suppurative, and is expectorated in large quantities. At this period, if the disease remains unchecked, the limits of the lung tissue are passed and the infection attacks the pleura. A moderately strong fetid odor may become manifest at this stage of the disease, but this symptom in itself should not be considered pathognomonic of pulmonary actinomycosis and no specific value should be given to that symptom in regard to the diagnosis. Any severe wasting disease may produce that particular symptom. Only when actinomyces are found in the sputum, in the pleural exudate, or in the pus from the sinuses, may the true diagnosis be suspected. Roentgenoscopy more often misleads than helps. It often leads to incorrect diagnosis because the roentgen picture will strikingly resemble pulmonary tuberculosis, bronchiectasis, malignant tumors, or pulmonary abscesses, and the differentiation is extremely difficult. In other words, correct diagnosis is based mainly on the bacteriologic demonstration of actinomycotic filaments on ordinary smears and repeated cultures. The appearance of the characteristic yellow grains, so-called sulphogranules is not a necessary prerequisite for a clinical diagnosis since the

infection may be caused by a type of fungi devoid of that characteristic. The patient's history may be of tremendous help. Extraction of infected teeth prior to developing the infection should always be considered as a possible clue to the diagnosis. The frequency with which actinomycosis follows dental procedures should be emphasized. The disease may develop following dental extraction, treatment of pyorrhea, and various other inflammatory conditions of the mouth. It is important, therefore, to remember that all types of dental infections may be associated with actinomycotic infection. However, it is no less significant to keep in mind that ray fungus is known to be a frequent inhabitant in the mouth of many individuals with good oral hygiene.

#### *Prognosis*

From the study of cases of pulmonary actinomycosis reported in the literature one may easily conclude that the prognosis is, as a rule, unfavorable. Almost all authorities agree that when the disease has metastasized to different parts of the body, the prognosis is always poor. Practically all cases of extensive pulmonary actinomycosis in the lungs which were reported in the English and American literature had fatal results. Apparently, in the pulmonary form the prognosis is less favorable than in other forms because, up to the present time, no effective therapy has been offered. Iodides, thymol and roentgen therapy were reported helpful, but seldom were effective in regard to cure. Sulfanilamide was recently suggested, but no cases have been reported where sulfanilamide therapy were used.

In our case, sulfanilamide produced good results for a limited period of time, but the treatment was not sufficient to accomplish a cure. The therapy, therefore, remains a difficult problem. The difficulty lies in the fact that thoracic cases are usually diagnosed when there is already extensive involvement of the lungs and at that stage even heroic measures are of little help. Early recognition of the disease is, therefore, of tremendous importance as far as prognosis is concerned.

#### *Case Report*

H. M., white, male, age 49, was admitted to Glenn Dale Sanatorium on November 29,

1939. On admission he stated that his health had failed generally since the middle of July, 1939, when on the advice of his dentist all of his teeth were extracted (17 in number) under novacaine anesthesia. Apparently there was an extensive pyorrheal infection; x-ray of teeth taken previous to extraction showed evidence of destruction of alveolar processes and diseased periapical regions in a number of them. He also had a severe cold, which, according to his statement, lasted for over three weeks. By September, 1939, he commenced to have pain in the left chest and about the same time developed a persistent productive cough. He felt quite tired, had numerous night sweats, lost considerable weight. He was put to bed and as he did not show any improvement, he entered a general hospital in November, 1939. A diagnosis of pulmonary tuberculosis with cavitation in the left upper lobe was made and left artificial pneumothorax instituted. However, the record of that hospital shows that no acid-fast bacilli were found (several concentrated specimens) and that "spores and mycelia present in sufficient number to suggest the desirability of a culture being made." Shortly after institution of pneumothorax he was referred to Glenn Dale Sanatorium. A total of five refills were given before he was admitted. At the time of admission to Glenn Dale he had a severe productive cough; temperature was elevated, ranging from 98° to 103°; pulse rate from 88 to 132; respirations from 24 to 36.

#### *Physical Examination*

The patient's condition on admission was very poor. He appeared older than the given age, showed extreme emaciation with a tremendous loss of subcutaneous fat and wasting of the muscles. He was surprisingly alert, fully oriented, and quite cooperative. On the lower left posterior part of the skull there was an infected area with some purulent discharge. Shortly after admission smaller infected areas were noticed over the prominence of the first joint of the left thumb, right lower leg, and left lower chest posteriorly. All of these cutaneous lesions were red, somewhat raised, punched out ulcerated nodules, exuding purulent material. The skin margin surrounding the ulcerated areas was indurated and showed a reddish purple discoloration. The cervical and epitrochlear

nodes were not palpable. All the teeth had been removed. The gums showed no evidence of any lesion.

*Lungs*—The body thorax was rather long and narrow. The left side did not perceptibly expand, though some motion was felt on palpation. The fremitus was intense over the right side but poorly felt over the left, front, and lateral portion. On percussion the note was tympanitic over the entire left chest, front and lateral, and almost equally so over the right chest down to the costal margin, the liver dullness being obliterated. On auscultation, breath sounds on the left side were heard faintly over the upper, inner chest, and scattered over the entire left chest occasional rather tinkling rales were heard. Over the right chest anteriorly the breath sounds were markedly accentuated down almost to the costal margin. Whispered and spoken voice sounds were suppressed over the left chest but increased over the right chest anteriorly. The posterior portion of the chest showed signs about the same as in front.

*Heart*—The apex beat was not localized. The sounds were somewhat distant, rapid, regular, without any definite murmurs or arrhythmias. The cardiac dullness could not be delineated; the pulses were equal and regular.

*Abdomen*—The abdomen was scaphoid in shape without any adipose tissue. No tenderness or masses. The liver, spleen, and kidneys were not felt.

Several weeks following admission there appeared over the insertion of the left deltoid a rounded, soft, fluctuant, slightly purplish mass which was a bit tender; also a diffused swelling about the right elbow joint, where motion was limited, with some tenderness. The capsule of the joint seemed definitely distended. Similarly, the left knee joint was markedly distended, extremely tender, and painful with definite limitation of flexion. The patella was high and fixed.

#### *Laboratory Findings*

Sputum produced in large amount was thick, tenacious, muco-purulent in character. It was persistently negative for tubercle-bacilli on direct smears, concentration, and culture. The stained smears revealed numerous long, granular, interlacing, branching filaments with no ray formation. Macroscopically no granules could be detected. In the

earlier specimens no club formation was noted, but as the disease progressed, club-shaped swellings were found on the ends of the filaments. The filaments were gram-positive, retaining the stain unevenly. When stained by Ziehl-Neelsen method, the granules of the filaments retained the acid-fast stain while the main body did not. When the sputum was inoculated on blood agar plates and Hohn's egg media and incubated for 36 hours at 37° C, a white, dry, chalky, tough, somewhat raised growth was obtained on the surface. After several days there was a pronounced wrinkling of the growth and the color deepened to a light orange.

Attempts to grow the organism under anaerobic conditions were unsuccessful. This organism with the exception of being non-acid-fast had all the characteristics of that isolated and discussed by Eppinger in 1891<sup>1</sup> and now generally classified as *actinomyces asteroides*. Aspirated material from the abscesses on the arm, knee, scalp, and other infected areas showed identical characteristics. They did not reveal the presence of any granules. All smears showed the *actinomyces* filaments and pure cultures of *actinomyces asteroides* were obtained repeatedly. No tubercle bacilli nor any other organisms except *actinomyces asteroides* were obtained at any time on smears or cultures (blood agar, Hohn's media, broth). Apparently the strain of *actinomyces* obtained from sputum and purulent material aspirated from several metastasized abscesses were identical from bacteriological and cultural standpoints, that is, they showed definite characteristics of *actinomyces asteroides* except that they took the acid-fast stain very poorly. Guinea pig inoculated in the peritoneum with 3 cc. of the concentration of the purulent material and killed six weeks later showed no evidence of tuberculosis or actinomycosis.

*Blood*—Due to the fact that the patient was on a prolonged sulfanilamide regime, practically daily hemograms were taken. They ranged as follows:

Hg:	40-63%
R.B.C.	2,460,000 — 3,890,000
W.B.C.	11,600 — 44,000

#### *Differential*

Leukocytes:	8—76%
Monocytes:	1—14%

Young forms: 2—9%  
 Band forms: 5—39%  
 Segmented forms: 5—74%  
 Neutrophiles 17—82%  
 Occasional eosinophile and basophile.

#### *Blood chemistry*

12/22/39—Free blood sulfanilamide 10.6 mgs.  
 12/26/39—Free blood sulfanilamide 10.1 mgs.  
 1/12/40—Free blood sulfanilamide 13. mgs.  
 Leukocytic Index: 100 plus.  
 Sedimentation rate ranged from 24 to 29.5 mm. per 60 minutes.  
 Wassermann negative.

*Urine*—Amber in color, always cloudy in appearance, negative for sugar, positive for albumen in each specimen. Microscopically, a few leukocytes and occasionally some fine granular and hyalin casts were seen.

*P.S.P. test*—A total of 93 per cent of dye excreted in 2 hours following injection of dye (shortly after admission).

*Roentgenography*—The film taken on admission showed dense infiltration of the upper half of the right lung. On the left side the film showed small pneumothorax collapse of the lower two-thirds of the lung with a horizontal fluid line, approximately reaching the upper border of the fourth rib anteriorly. The upper left lung area was filled with rather soft infiltration. Several annular rings suggesting cavities were seen in that area. There was no evidence of bone involvement on admission. Several weeks later, however, the left knee became red, painful, markedly swollen; osteomyelitis rapidly developed with subsequent complete destruction of the knee joint.

#### *Course in the Hospital*

The patient was admitted in critical condition. He had an artificial pneumothorax instituted before admission and apparently developed fluid in his chest. The collapse therapy was done on the supposition that the lesion was tuberculous. As soon as the diagnosis of actinomycosis was proved, intensive iodine treatment was prescribed. As no appreciable results were obtained in a period of ten days, the patient was put on sulfanilamide treatment supplemented with nicotinic acid and Vitamin B-1. Transfusions were frequently given. During the first six weeks of this treatment the patient showed

considerable improvement. His temperature came down to normal; pulse and respirations were normal; he gained weight and in general was very comfortable. The abscesses were healing rather rapidly and the little discharge which was still present did not show any more actinomyces on ordinary smears and cultures. The results of treatment up to this time were extremely encouraging. He coughed very little and the amount of expectoration decreased greatly. X-ray also showed evidence of considerable clearance on the right side, but the left side showed a gradual increase in the amount of collapse of the lung. Apparently, there was a tension pneumothorax with a definite simultaneous increase in the amount of fluid in the pleural cavity. The fluid proved to be yellow, purulent material with a putrid odor, containing many gram-positive cocci. No tubercle bacilli or actinomyces were found in the fluid.

The air and fluid were aspirated several times in order to expand the lung. We were not successful in obtaining that result. His left pneumothorax continued to increase; also the fluid in the pleural cavity. In the latter part of January his temperature began to elevate to 101°, 102°. Several additional metastatic abscesses developed from which we again could obtain actinomyces asteroides on smears and cultures. At that time the treatment had no effect whatever. He finally developed a generalized edema, severe dyspnea, and a rapid down-hill course followed. He died on March 22, 1940.

#### *Autopsy Report*

The patient was a white, markedly emaciated male, whose estimated body length was 5 ft. 6 in., and weight approximately 120 pounds. On the head there was a purplish area in the left occipital region, 5 cm. in diameter, which contained 3 open wounds, the largest being 3 mm. in diameter. The mucous membrane was markedly pale. There was grade 4 pitting oedema of the right hand, and grade 1 pitting oedema of the left hand.

*External marks*—An area a few mm. in diameter which exuded pus, foul smelling, and of brownish nature over middle one-third of the left femur. There were several puncture wounds in left axilla. The left knee was markedly swollen. Medially and laterally there were 2 incisions 1½ cm. long from which

exuded a light brown, puriform material which was foul smelling.

*Peritoneal cavity*—There was about 35 cc. of clear straw colored fluid present. There were no adhesions. The lymph glands were slightly enlarged. The peritoneum was smooth and shiny.

*Pericardial cavity*—There was about 20 cc. of clear straw colored fluid present.

*Pleural cavities*—In the left pleural cavity there was approximately 750 cc. of dark green, thick, purulent fluid. The right pleural cavity contained no fluid; there were numerous fibrous adhesions present at the apex.

*Heart*—The heart was normal in size. The pericardium was smooth, and all valves were normal. The heart muscle was firm and of a brownish color. The coronaries were tortuous, and showed grade 1 atheroma.

*Lungs*—The entire left lung was bound down and atelectatic. The pleura was thickened to about 3 mm. and on section the lung seemed to have numerous, scattered, yellowish-gray areas, mainly arranged about the terminal bronchioles. There were numerous bronchiectatic areas throughout the entire lung substance. The upper one-third consisted of a hollowed-out, trabeculated, roughened cavity which was empty. Several of these yellowish areas were broken down and exuded a yellowish-brown material.

The right lung was markedly voluminous, and crepitant throughout. On section the upper lobe revealed a single isolated lesion approximately 5 cm. in diameter which on cutting into revealed several small communicating cavities, which were lined by a smooth membrane and contained purulent material. The middle lobe was atelectatic and almost completely airless. The lower lobe was a purplish red in color, quite firm, and in its lower half and on section considerable sero-sanguinous fluid could be expressed.

*Spleen*—This was enlarged to  $1\frac{1}{2}$  times the normal size. The capsule was smooth, and on section showed considerable congestion and several calcified pin-head sized yellow nodules.

*Liver*—Normal in size, considerably congested. On section the liver was chocolate brown in color and showed grade I nutmegging.

*Adrenals*—Normal.

*Kidneys*—The left kidney was enlarged  $1\frac{1}{2}$  times, and the capsule stripped with ease.

On section, the organ was intensely congested. In the pelvis and calyces were found some yellowish-brown, finely granular, hard substances. The right kidney, normal in size, showed similar findings.

*Bladder*—Contained stones similar to those in the kidneys. Otherwise, normal.

*Prostate*—Enlarged and contained a few adenomatous nodules.

*Pancreas*—Normal.

*G. I. Tract*—Normal.

*Knee*—On opening into the left knee joint, there was crumbling of lower end of left femur and considerable erosion was present. The joint cavity contained about 300 cc. of green purulent material.

#### *Microscopic Examination*

*Heart*—The fibers were vacuolated and torn asunder by freezing.

*Aorta*—Showed atheromatous plaques.

*Lungs*—(14 sections). All but two showed the same picture—discrete and confluent granulomatous lesions characterized by extensive proliferation of fibroblasts causing extensive scarring, obliteration of bronchioles and alveoli, and carnification. The granulation tissue was infiltrated with polys and macrophages in some areas, but not in all. A few sections showed frank abscesses walled off by granulation tissue. About the periphery of these abscesses and in other areas were peculiar deeply eosin staining hyaline necrotic areas about  $1/10$  mm. in diameter surrounded by invaded "epithelioid cells" but no giant cells. Everywhere associated with the granulomatous lesions appeared a very large characteristic and striking circular to oval cell-like or yeast-like bodies 4 to 6 times as large as a macrophage. This body had a very dark staining "blotch-like" nucleus quite unlike that of a tissue cell (no chromatin granules) which was often surrounded by a narrow clear zone. The cytoplasm was abundant in amount and was either dark and indistinct or was distinctly granular. In some cells the granules were very distinct. There was no definite ectoplasm. No ray fungi or sulphur granules were seen anywhere. No tuberculosis was present. One section showed a diffuse polymorphonuclear infiltration—the typical picture of terminal bronchopneumonia.

*Spleen*—Large amount of intracellular hemosiderin—hemosiderosis.

*Kidney*—Architecturally normal.

*Prostate*—Well marked hyperplasia associated with dilated acini lined by very flat epithelium. Pus was seen in many acini.

#### *Anatomical Diagnosis*

Left pleural emphysema.

Fungus infection—left lung and right upper lobe with cavitation and bronchiectasis.

Osteomyelitis—left femur with acute septic arthritis—left knee.

Sinus of scalp.

Renal and bladder calculi (acetyl sulfapyridine?).

Hepatic and renal congestion.

#### *Clinical Diagnosis*

Generalized Actinomycosis complicated by left pneumothorax.

#### *Comment*

A case of advanced bilateral pulmonary actinomycosis complicated by artificial pneumothorax with a number of metastases to

different parts of the body is reported. In reviewing the literature, one finds very few cases of actinomycosis in which the disease is limited to the lung bed. It is, therefore, of utmost importance to give to the clinician, and particularly the one who is primarily interested in respiratory diseases, a syndrome on which the diagnosis of this condition may be made. History of teeth extraction, indefinite persistent pain in the chest, associated with a productive cough of a mucoid or purulent sputum, loss of weight, weakness and emaciation, all of these symptoms should be considered of sufficient importance to rule out actinomycosis, particularly so if the sputum remains persistently negative for acid-fast bacilli. There is usually secondary anemia, moderate leukocytosis, and a considerable increase in granulocytes. Temperature is septic with an increasingly associated rise

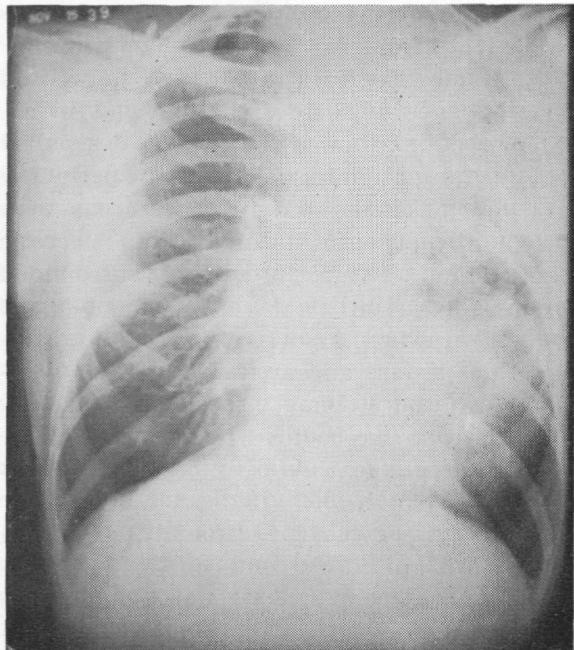


FIGURE 1

X-ray taken before any treatment was instituted. The right lung field appears to be free from definite pathology except for peribronchial infiltration in and around the hilum. The upper three-fourths of the left lung is filled with a dense, nearly completely opaque, caseofibrous infiltration. There is a lighter area in the upper fourth suggesting a large cavity. The pathology of this film strikingly resembles pulmonary tuberculosis.

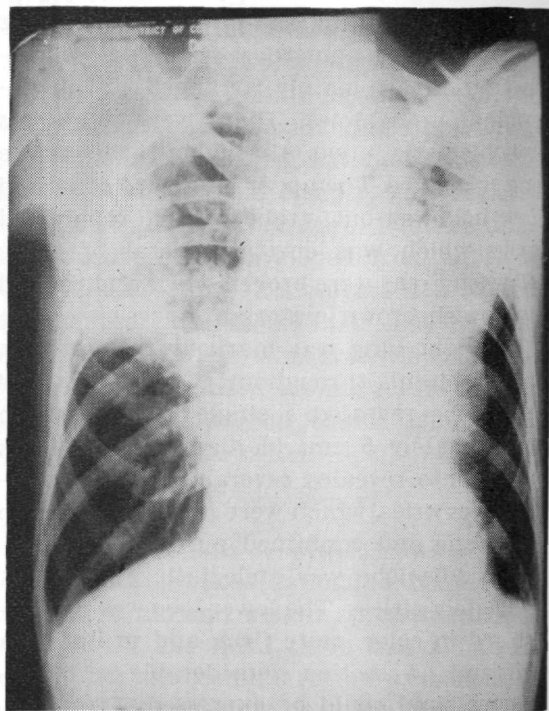


FIGURE 2

This plate was taken following institution of left pneumothorax on the assumption that the pathology was pulmonary tuberculosis, advanced lesion with cavitation. The left lung field shows a 20 per cent marginal pneumothorax collapse below the third rib with a small amount of fluid in the costo-phrenic angle. The collapsed lung is nearly completely opaque except for the upper third where several areas of lesser density, suggesting cavities, were seen. Following institution of pneumothorax there apparently appeared a spread of pathology to the right and the plate shows the upper half of the right lung filled with a dense caseo-fibrous infiltration.



in the pulse rate. The symptoms of actinomycosis of the lung may resemble that of bronchitis, bronchopneumonia, or pulmonary abscess. However, pulmonary tuberculosis is naturally the condition with which it is most apt to be confused because the clinical picture of pulmonary actinomycosis and tuberculosis simulate each other very closely. The differential diagnosis will depend entirely on the laboratory findings, the recovery of specific fungus on ordinary smears and cultures. Primary actinomycosis of the lung is usually a bronchopneumonic form. Cough and expectoration are practically identical with those of a tuberculous lesion. The roentgenogram is also strikingly similar to that of pulmonary tuberculosis of advanced stage.

Pathologically, actinomyces produce in the human organism such disintegration and destruction of normal tissue that the process has almost malignant characteristics. When actinomycosis affects the lungs, primarily, it tends to produce large solitary abscesses (cavities); the infection is also characteristically associated with multiple metastatic sinuses.

Early recognition of the disease is of tremendous importance. Adequate sulfanilamide treatment, supplemented by small transfusions, in that stage may effect recovery.

Pneumothorax therapy is not indicated and should not be instituted in cases where diagnosis of actinomycosis is suspected.

Glenn Dale Sanatorium.

#### Reference

- 1 Eppinger, Hans: *Beitr. Anat. Allg. Path.*, pp. 278-328, September, 1890.

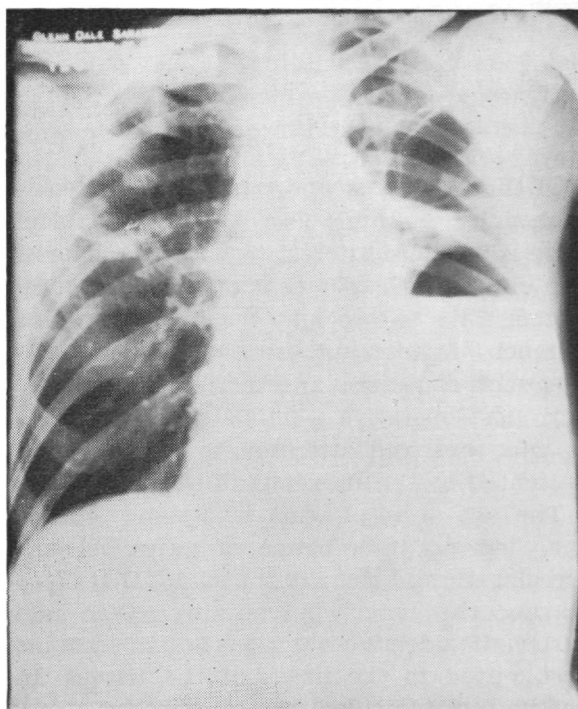


FIGURE 3

This plate was taken following vigorous sulfanilamide treatment. The right lung field has cleared considerably, leaving some evidence of moderate infiltration in the upper two-thirds. The left side shows increased tension pneumothorax limited below at the level of the third anterior rib by a horizontal fluid line. The collapsed lung is adherent to the apex at the level of the second interspace. The infiltration in this area has become much less dense.

We wish to thank Dr. C. W. Emmons, Senior Mycologist, U. S. Public Health Service, for his interest and valuable cooperation in helping to identify the cultural characteristics of the isolated organism. We also extend our appreciation to Mr. Tomas Jefferis, Senior Medical Technologist of the Glenn Dale Sanatorium, whose untiring efforts and assistance were most helpful in establishing the correct diagnosis.

THE SEED IS SOWN—(Cont. from page 226) them by x-ray examination and repeated examination of the sputum. Viewed from the narrowed vision of epidemiology; an attack of influenza is not strictly the etiological factor in tuberculosis; but clinically it frequently may be the starting point at which the spark of a latent or dormant infection is fanned into burning flame. It frequently serves to

orient the patient as the time of his departure from normal health. These individuals are now purchasing tonics, vitamins or coming to your office for a helpful suggestion. Keep tuberculosis in mind and look for it. You will find it in a surprising number of instances. The harvest is coming in. Reap it well!

C. H. H.